

A rare case of myocardial bridge involving left anterior descending, obtuse marginal and ramus intermediate coronary arteries

Tuncay Kiris¹, Diyar Koprulu¹, Muzaffer Elmali², Gonul Zeren¹, Guney Erdogan³

¹Ordu State Hospital, Ordu, Turkey

²Radiology Department, Faculty of Medicine, Ondokuz Mayıs University, Samsun, Turkey

³Fatsa State Hospital, Ordu, Turkey

Kardiochirurgia i Torakochirurgia Polska 2016; 13 (4): 368-369

Abstract

Myocardial bridging, a congenital coronary anomaly, is a cluster of myocardial fibers crossing over the epicardial coronary arteries. It is most frequently seen in the left anterior descending artery (LAD), and rarely involves the circumflex (CX) and right coronary artery (RCA). We report a patient with an unusual coronary bridge crossing over the left anterior descending, obtuse marginal and ramus intermediate branches. The patient presented with exercise-induced angina pectoris that was relieved with medical therapy.

Key words: myocardial bridging, angina pectoris.

Streszczenie

Mostki mięśniowe to wrodzona anomalia wieńcowa polegająca na przebiegu pasm mięśnia sercowego nad tętnicami wieńcowymi nasierdza. Najczęściej obserwuje się je na gałęzi przedniej zstępującej lewej tętnicy wieńcowej (LAD), rzadko na gałęzi okalającej (Cx) lub prawej tętnicy wieńcowej (RCA). Przedstawiamy przypadek pacjenta z nietypowym mostkiem wieńcowym przebiegającym nad gałęzią przednią zstępującą, gałęzią brzozną lewą (OM) i gałęzią pośrednią (*ramus intermedia*). Pacjent ten zgłosił się z wysiłkową dusznicą bolesną, którą uśmierzono za pomocą terapii medycznej.

Słowa kluczowe: mostki mięśniowe, dusznica bolesna.

Case report

A 46-year-old man presented with recurrent retrosternal chest pain of 3 months duration. He had a history of smoking. No physical abnormality was detected by examination. Electrocardiogram, blood test and echocardiography were normal. While doing the treadmill exercise test, the patient developed chest pain and significant ST segment depression in lateral precordial leads of the second stage. We decided to perform coronary angiography. Myocardial bridge was observed in the large segment of the left anterior descending artery (LAD), ramus intermediate and first obtuse marginal branch. We also performed multislice computed tomography (CT), which showed a large segment of both the circumflex (CX)-OM1 and LAD buried in the myocardium of the left ventricle (Figs. 1, 2). Medical treatment was given and he was symptom-free for 5 months.

Discussion

Myocardial bridging occurs when the epicardial coronary arteries are intramyocardial, resulting in systolic compression of a coronary artery on coronary angiography. The incidence is higher at autopsy (15–85%) than at coronary

angiography (0.51–2.5%) [1]. Myocardial bridges are usually found over the left anterior descending coronary artery; they are very rarely found over the right coronary artery or the left circumflex coronary artery. Angelini *et al.* [2] reported that out of 61 patients with a myocardial bridge, only one had an additional myocardial bridge of the posterior descending branch of the right coronary artery. In the literature, there are few reported cases of a myocardial bridge in the left circumflex coronary artery [3]. One of these reported patients had myocardial infarction treated by stenting of the bridged segment [4].

An interesting point about our case is that the myocardial bridge involved the large segment of the LAD, ramus intermediate and first obtuse marginal branch. To our knowledge this is the second reported case of myocardial bridge involving the large segment of the LAD, ramus intermediate and first obtuse marginal branch coronary artery. The first reported case was by Kumar *et al.*, in which their patient had main branches involving the left main coronary artery (LMCA) and both LAD and CX coronary arteries [5].

Controversy exists concerning its clinical and prognostic relevance and the appropriate therapeutic approach for symptomatic patients. There are three potential therapeutic

Address for correspondence: Dr. Tuncay Kiris, Ordu State Hospital, Sahincili Mah., 52000 Ordu, Turkey, phone +90 5056289406, e-mail: drtkiris@hotmail.com

Received: 25.02.2013, **accepted:** 14.10.2016.

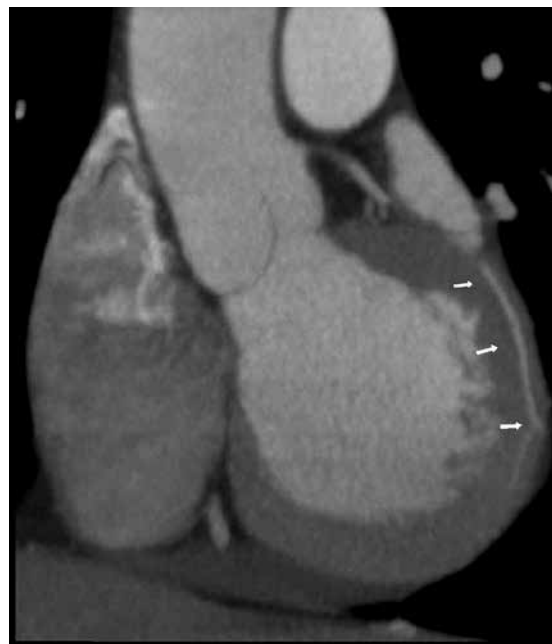
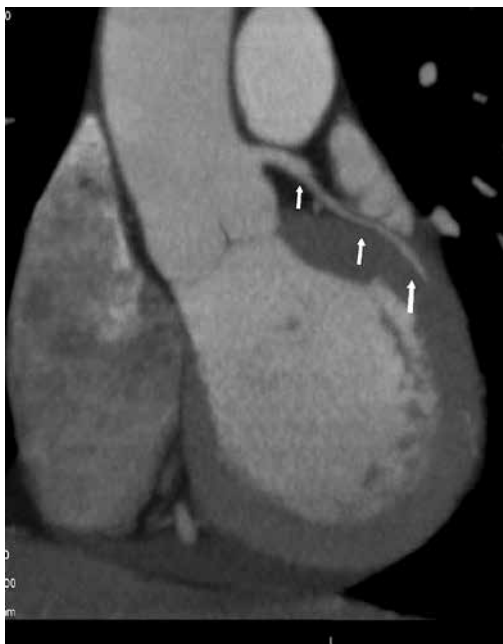
Fig. 1. Reformatted semicoronary image showing intramyocardial trace of long segment of the first obtuse marginal branch

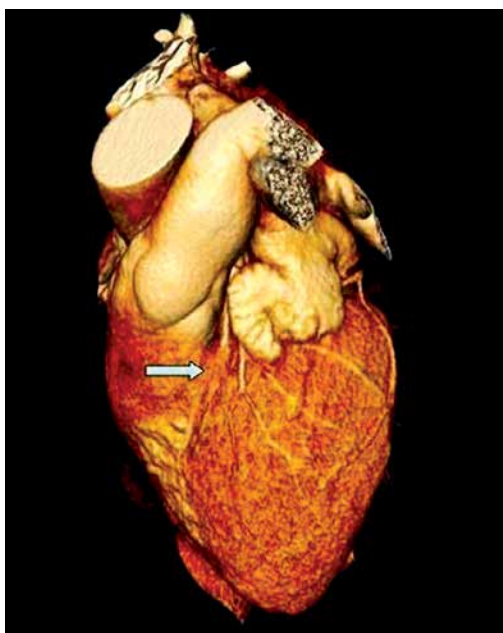


Fig. 2. 3D volume rendered computed tomography image showing a myocardial bridge in the proximal segment of the left anterior descending artery

strategies: pharmacological intervention, surgical myotomy and bypass grafting, and percutaneous angioplasty with stent implantation. Studies have suggested that tachycardia

may worsen ischemia due to a reduction of the diastolic coronary filling duration. Negative inotropic agents, especially β -blockers, are capable of reducing systemic and intramural pressures and thereby the external vessel compression. The accompanying negative inotropic effect mainly prolongs diastole, but also improves coronary perfusion.

Surgical myotomy was not suitable in our patient because of the large segment involvement, so we preferred to use a β -blocker as the first line of treatment and successfully relieved the exercise-induced angina, and he is now doing well without any symptoms.

Disclosure

Authors report no conflict of interest.

References

1. Noble J, Bourassa MG, Petitclerc R, Dyrda I. Myocardial bridging and milking effect of the left anterior descending coronary artery: normal variant or obstruction? *Am J Cardiol* 1976; 37: 993-999.
2. Angelini P, Trivellato M, Donis J, Leachman RD. Myocardial bridges: a review. *Prog Cardiovasc Dis* 1983; 26: 75-88.
3. Okmen E, Oguz E, Erdinler I, Sanli A, Cam N. Left circumflex coronary artery bridging. *Jpn Heart J* 2002; 43: 423-427.
4. Arjomand H, ALSalman J, Azain J, Amin D. Myocardial bridging of left circumflex coronary artery associated with acute myocardial infarction. *J Invasive Cardiol* 2000; 12: 431-434.
5. Kumar B, Wardhan H, Nath RK, Sharma A. A rare case of myocardial bridge involving left main, left circumflex, and left anterior descending coronary arteries. *J Am Coll Cardiol* 2012; 59: 965.